

14 PATHFINDER™ CORNEAL ANALYSIS

INTRODUCTION

PathFinder Corneal Analysis is a software program designed specifically for corneal topography to identify abnormal, pathologic, and normal corneas based on statistical indices derived from the Humphrey ATLAS™, ATLAS Eclipse™ and MasterVue™ Corneal Topography systems. Some of these indices are exclusive to Humphrey corneal topography, and therefore make this software analysis unique when compared to other software programs available that examine the cornea for pathology or abnormal surface conditions.

The three statistical indices that PathFinder uses to gauge the shape, regularity, and toricity of the corneal surface are Corneal Irregularity Measurement (CIM), Shape Factor (SF), and Mean Toric Keratometry (TKM). Isolating and identifying normal versus abnormal populations using these three parameters by examining hundreds of topography exams has been done in order to achieve the high level of sensitivity and specificity that the software is able to accomplish.

STATISTICAL INDICES AND NORMAL POPULATIONS

Shape Factor (SF) is a measure of the asphericity of the cornea, and a derivative of eccentricity, which is a well known calculation of corneal shape used by contact lens fitters. Shape factor can be used to determine whether the cornea is more oval or elliptical shaped, by assigning a factor, or index, to represent the shape of that surface. Shape factors are unique and different from eccentricity in that it is possible to calculate a negative, or oblate shape, as well as a positive, or prolate shape. The less spherical, or more elliptical the cornea is in the horizontal meridian, the more the cornea will resemble a prolate shape. One could imagine this shape being like an egg turned on its pointed end, as in this example, where the center of the cornea is much steeper in curvature than the periphery. Highly positive or prolate shape factors may imply that a pathology such as keratoconus may exist. The less spherical, or more elliptical the cornea is in the vertical meridian indicates an oblate shape. This shape would be the reverse of the egg on its pointed end, and would resemble an egg lying on its side, such as this .

This type of negative or oblate shape would mimic a post refractive surgery eye, with the center being flatter than the periphery. A perfect sphere would therefore have a Shape Factor of zero, and would resemble the shape of a perfect circle, such as this .

Normal Shape Factors usually range from .13 - .35 in the normal population but can be in the .2 - .3 range. When the shape factor reaches .7 and above, the cornea begins to exhibit a more conical shape, and usually indicates some sort of pathology or abnormal shape.

Shape Factor ranges occur in the human population as follows:

Normal - .13 to .35
Borderline - .02 to .12, .36 to .46
Abnormal - - 1.0 to .01, .47 to 1.0

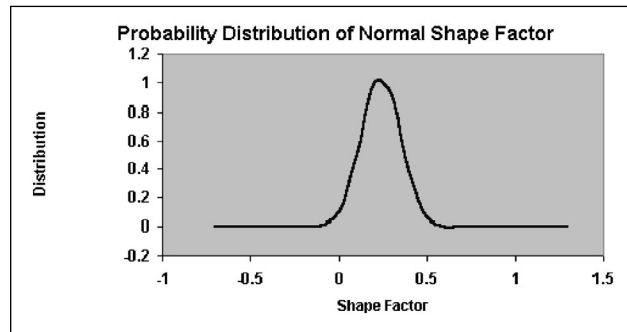
The normal distribution in the human population appears as a bell shaped curve where the mean value is .24 while 96% of the population falls between 0 and .46.

The mathematical formula for shape factor is:

$$E_p = e^2 = 1 - p_p \text{ where } E_p \text{ is a prolate shape}$$

and

$$E_o = \frac{-e^2}{1 - e^2} \text{ where } E_o \text{ is an oblate shape.}$$

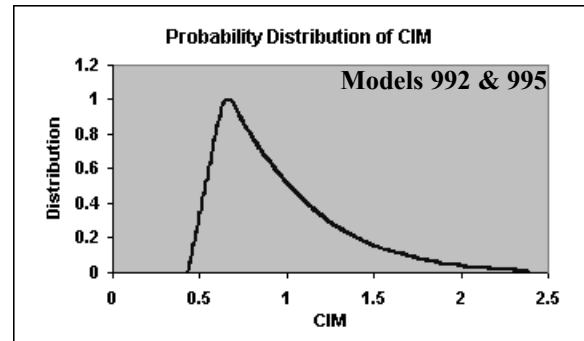
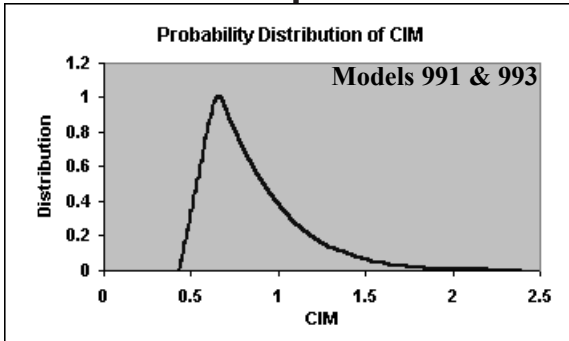


Corneal Irregularity Measurement (CIM) is a number or index assigned to represent the irregularity of the corneal surface. The higher the irregularity index, the more uncorrectable or uneven the surface is optically, thereby highlighting irregular astigmatism that often results in visual distortions. CIM uses the thousands of data points within the first ten rings of the corneal topography data to determine the difference in "height" or elevation between the patients cornea and a perfect model toric cornea. The difference between the perfect model and the actual cornea is measured in microns and the standard deviation is taken. This is defined as CIM. Higher CIM values, then, would tend to indicate a worsening pathology such as keratoconus, due to the inherent corneal thinning and "wrinkling" of the corneal surface that the pathology causes. High CIM indices can also be observed in post refractive surgery corneas due to the irregularity that the surgical procedure and subsequent healing process cause. CIM normal values appear in the table below; they range from

0.4 to 0.8 or 0.9 microns, depending on the model. The higher the number becomes, the more abnormal it is. When CIM values are measured at 1.0 microns and above, severe corneal distortion is usually present.

	<u>Models 991 & 993</u>	<u>Models 992 & 995</u>
<u>Normal</u> -	0 to 0.80	0 to 0.90
<u>Borderline</u> -	0.81 to 1.00	0.91 to 1.10
<u>Abnormal</u> -	>1.00	>1.10

67% of the population falls in the normal range. The infrared Models 992 & 995 have more noise, which accounts for the difference in the ranges. A bell shaped distribution curve is not seen due to the fact that no negative numbers can be calculated using CIM, resulting in a skewed distribution plot.



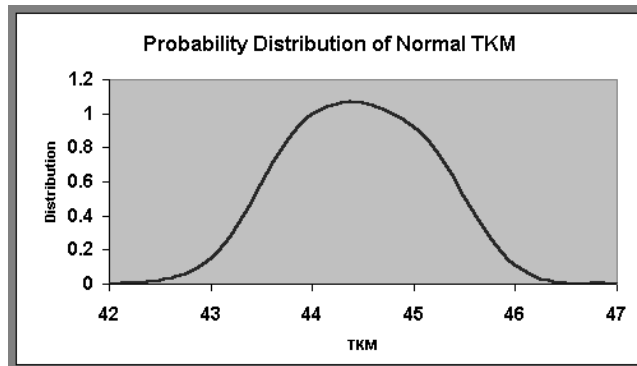
Mean Toric "K" (TKM) is the value which is derived using elevation data from a best fit toric reference surface as compared to the actual cornea. Two values are calculated at the apex of the flattest meridian and their mean is determined. This is described as the mean value of apical curvature. The higher the TKM index becomes, the greater likelihood that excessive corneal toricity exists, which often leads to keratoconus. By fitting the topography of the patient's cornea to a best fit reference toric, all of the correctable sphere and cylinder can be accounted for in the topographical data, thereby giving the most accurate toric representation of the patient's cornea possible.

**Definition of Conditions
Identified by PathFinder**

The ranges for TKM in the population are as follows:

<u>Normal</u> -	43.1 to 45.9
<u>Borderline</u> -	41.8 to 43, 46 to 47.2
<u>Abnormal</u> -	36 to 41.7, 47.3 to 60

The distribution appears as a bell shaped curve where the mean value for TKM is 44.5 and 96% of the population falls between 41.25 and 47.25 diopters.



Isolating and identifying normal versus abnormal populations has been determined using the three statistical indices (CIM, SF, MTK) in the examination of hundreds of topography exams. These exams act as a control group for the software to identify when a cornea is normal, just as when there is an abnormal condition.

Normal- The cornea is typically aspherical in shape with TKM, CIM and Shape Factor in the normal range. No abnormal topography patterns such as inferior steepening or abnormal elevation or curvature can be seen. These corneas may have a history of soft contact lens wear but no family history of keratoconus, excessive or irregular astigmatism, or rigid lens wear.

Corneal Distortion- (also known as pseudokeratoconus) is a condition caused by excessive RGP lens wear, where the poor fitting lens actually causes the inferior cornea to bulge outward, mimicking keratoconus on the topographical map, while no clinical or slit lamp findings are evident. The abnormal topography pattern may resolve or improve in a relatively short time period after removing the lens. The topographic pattern usually shows the cornea "bulging" rather than steepening abnormally, and there may also be signs of a compression ring, where the lens is "biting" or digging into the cornea. Some visual distortion symptoms may accompany this condition but usually diminish quickly after discontinuing lens wear. CIM may be outside normal limits, while Shape Factor and TKM remain within normal limits.

Sub-Clinical Keratoconus-(also known as forme fruste keratoconus) is usually distinguishable with the typical inferior nasal steepening topography pattern, but the cornea does not yet exhibit slit lamp findings typical of keratoconus. The steepening is noticeable on topography but can be well under 50 diopters at the apex of the cone. Often there is a history of the disease in the family, or the refractive history is unstable with a measurable increase in both myopia and astigmatism over the past several years. There may also be an inability to wear contact lenses, along with visual symptoms (reduced VA, ghosting, light sensitivity). CIM and TKM are likely to be outside normal limits in this condition, while Shape Factor will be within normal limits to slightly outside normal limits.

Keratoconus- is defined as the true pathological condition which causes thinning and wrinkling of the cornea, along with a cone-like protrusion of the cornea in it's later stages. Keratoconus can also produce high regular astigmatism, irregular astigmatism, and inferior steepening topographical patterns (usually nasal). Abnormal corneal findings observed under biomicroscopy to confirm a true keratoconus diagnosis may include but are not limited to: Vogt's striae, Munson's sign, Flesicher's ring, corneal ectasia, stromal thinning and superficial scars in Descemet's membrane. All three statistical indices, CIM, Shape Factor, and TKM will likely be outside normal limits with this condition.

Note: Decisions involving surgical procedures should be made only after considering *total* clinical information, and not on the basis of a single index or measurement.

To Access the PathFinder Corneal Analysis

PathFinder can be accessed two ways within the software. From the Main Menu screen, click on "Review", then select the patient and exam that you wish to evaluate. Select PathFinder Corneal Analysis from the drop down "Views" list box. Click on "OK" and the software will run and instantly provide the analysis using the standard Axial Map. The software can also be run from the MultiVue Displays/Optional Modules Screen. By clicking on the entry labeled "PathFinder Corneal Analysis" after selecting the desired patient and exam, the software will display the findings. Scaling can be changed from .25 diopter to .50 diopter increments simply by clicking on the AutoSize or Standard buttons respectively. To print the analysis, return to the Main Menu, or cancel the selection, click on Options, and follow the onscreen prompts.

PATHFINDER CORNEAL ANALYSIS SCREEN EXAMPLES

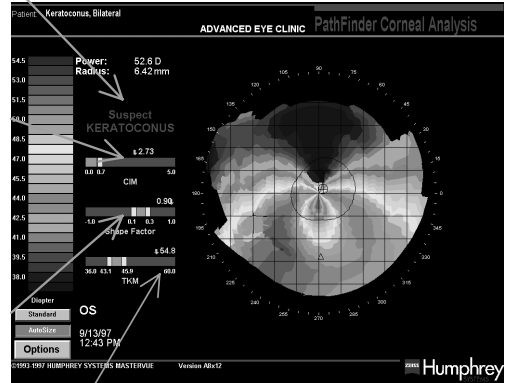
There are four different results that can be displayed when using the software, depending on the analysis:

The final result of the PathFinder Corneal Analysis is shown here.

CIM is a measure of irregularity taken from the difference between a best fit toric model and the actual corneal surface itself using highly sensitive elevation data.

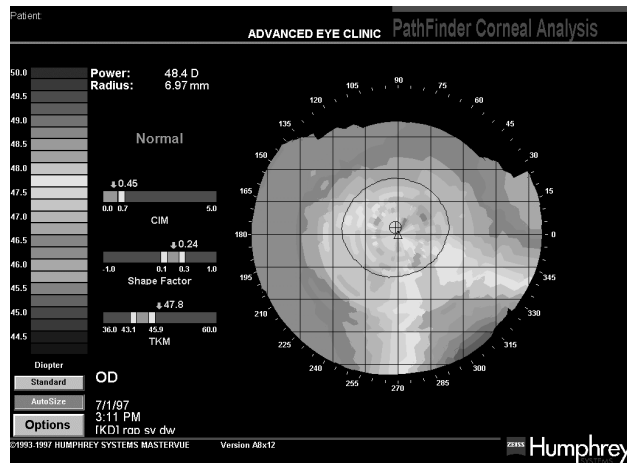
Shape Factor is a measure of the asphericity of the cornea, and a derivative of eccentricity, a well known measurement of corneal shape.

TKM is the mean toric keratometry measured as the difference between a best fit toric surface and the mean apical corneal curvature.



The red area of the bar indicates the abnormal range, while the yellow is borderline and the green is within normal limits. The index for this particular cornea is denoted above the bar and its location on the bar is indicated by an arrow.

NORMAL RESULT



NORMAL RESULT USING THE PATHFINDER CORNEAL ANALYSIS (FIG. 1)

The results of this analysis confirm a normal diagnosis as the statistical indicators CIM and SF are within normal limits while the TKM index is only borderline or slightly abnormal. If the TKM continues to increase or the CIM rises to an abnormal level over time, this cornea could be identified as corneal distortion. This may indicate a need to follow the patient long term to evaluate any changes that may be taking place.